

Bilateral breast reconstruction – Right delayed TUGs and Left immediate bipedicled DIEP (4 flaps at 2 separate operations)

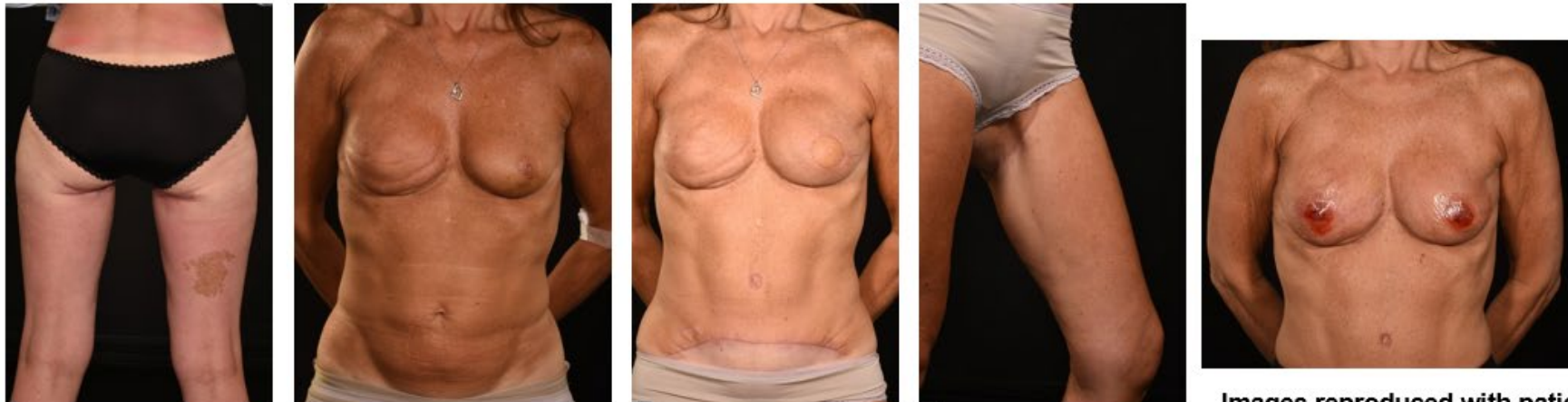
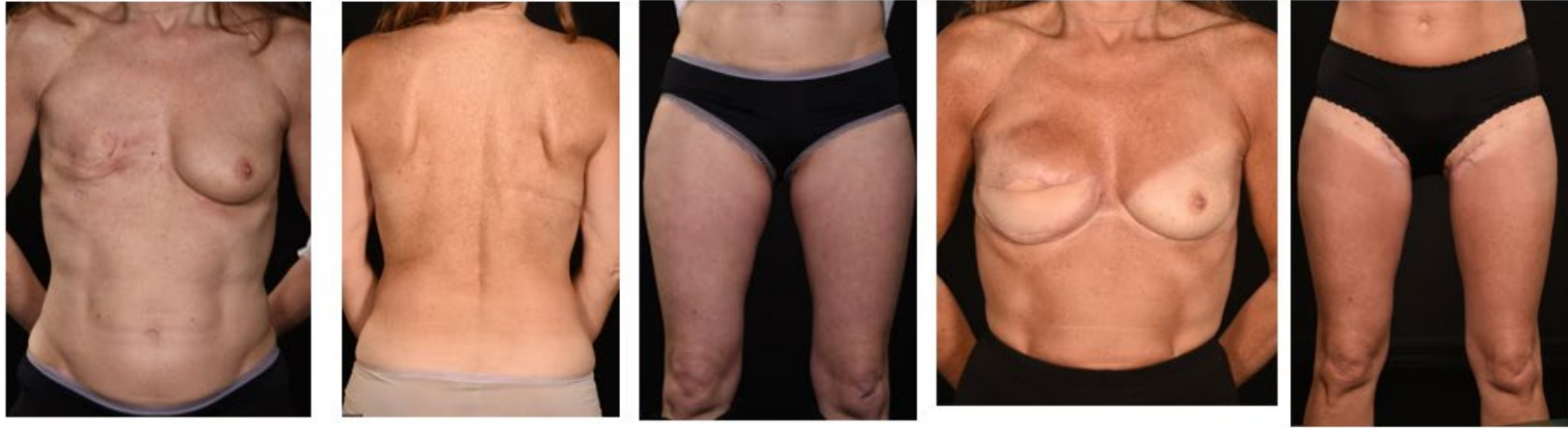1st procedure – Delayed Right reconstruction using bilateral TUG flaps after a failed implant reconstruction

2nd procedure 8 months later – Right breast scar revision & lipomodelling 3rd procedure 6 months later – Left skin-sparing mastectomy and immediate bipedicled DIEP flap

4th procedure 6 months later – Bilateral breast lipomodelling

5th procedure 13 months later – Bilateral breast lipomodelling
Bilateral 3D nipple & areola micropigmentation

Reconstructive journey completed in 33 months



Images reproduced with patient's consent.